

Disocclusion time–reduction therapy with immediate complete anterior guidance development to treat chronic myofascial pain-dysfunction syndrome

Robert B. Kerstein*

Successful treatment of chronic myofascial pain-dysfunction syndrome by disocclusion time–reduction therapy has been shown to be effective in 1 to 3 months, with the major muscular changes occurring in the first 30 to 40 days following initial therapy. Disocclusion time reductions have been previously reported to quickly reduce or eliminate numerous symptoms of chronic myofascial pain-dysfunction syndrome. Proper modification of an existing occlusal scheme from one that contains lengthy disocclusion time to one with short disocclusion time can be accomplished by implementing the method of occlusal adjustment known as immediate complete anterior guidance development. This paper describes the proper clinical occlusal adjustment methodology using a computerized device that shows the measurement and subsequent reduction of excessive disocclusion time. This directly lessens elevated contractile muscle activity, which leads to rapid muscular recovery of the involved dysfunctional muscle groups. (Quintessence Int 1992;23:735–747.)

Introduction

Lengthy disocclusion time (greater than 1.4 seconds) in the right and left mandibular excursions has been shown to elevate contractile muscle activity in seven female subjects with chronic myofascial pain-dysfunction syndrome (MPDS).¹

Proper reduction of lengthy disocclusion time has been successfully accomplished through the method of occlusal adjustment known as *immediate complete anterior guidance development* (ICAGD).¹ This new approach to occlusal therapy establishes immediate posterior disocclusion in all mandibular movements, prior to any habitual closure adjustments. This technique

has been shown to rapidly eliminate or dramatically reduce the clinical signs and symptoms of MPDS in a wide range of sufferers.^{1,2} It has also been verified that, once disocclusion time is properly reduced to less than half a second, it is a permanent occlusal change³ that allows the retention of proper muscle function. Short disocclusion time (less than 0.5 seconds) has been shown to reduce contractile muscle activity significantly to near resting state values during mandibular excursions. This in turn resulted in the rapid reductions of MPDS symptoms in seven female subjects approximately 1 month after the initial reduction of disocclusion time. Successful treatment of chronic MPDS by disocclusion time–reduction therapy is accomplished in 1 to 3 months, with the major muscular changes occurring in the first 30 to 40 days.^{1,2}

This is the first occlusal adjustment method that focuses on eccentric occlusion and not on how the teeth get into occlusal contact during a guided centric pathway closure movement or a habitual maximal intercuspal movement.

* Assistant Clinical Professor, Department of Restorative Dentistry, Tufts University, School of Dental Medicine, Boston, Massachusetts; Private Practice, 665 Beacon Street, Suite 204, Boston, Massachusetts 02215.

Immediate complete anterior guidance development is not occlusal equilibration as has been previously described by other authors.⁴⁻⁷ There are significant differences between the two procedures. In occlusal equilibration, the goal is guided centric relation closure, so that centric relation and centric occlusion are coincident. The result is an increase in molar contact.

There are no attempts to retrude the mandible during ICAGD. All jaw movements are free and unguided by the operator. Also, the sequence of adjustments is completely reversed from that of traditional occlusal equilibration. All mandibular excursions are adjusted and immediate posterior disocclusion in all excursions is established before any habitual closure adjustments are done.^{1,2} Molar contact is decreased.

The goal of ICAGD is to quickly disocclude the posterior teeth, primarily in the right and left excursions and secondarily in the protrusive movement. When this goal is accomplished, a new habitual, unguided, nonretruded closure position is refined with the patient's assistance and computer analysis by the T-Scan (Tekscan, Inc).⁸

Indications and contraindications

The use of ICAGD is indicated in patients who suffer from MPDS and who have some or all of their molars and premolars involved in lengthy disocclusion. This can occur in all skeletal jaw classifications.

The use of ICAGD is contraindicated in patients in whom the potential guiding teeth, ie, the premolars, canines, or incisors, are too far apart prior to treatment, so that excessive tooth adjustment would be required to bring them into guiding contact. This generally occurs in the patient with severe anterior open bite or severe Class II (division I) occlusion.

Also, patients younger than the ages of 13 to 15 should not be treated with ICAGD because their occlusion has not fully developed and would not be stable on completion of treatment.

Technique

Immediate complete anterior guidance development therapy is divided into two therapeutic phases: phase I = disocclusion time reduction to less than 0.5 seconds and phase II = refinement of the habitual closure position. Phase I is the key to muscular relaxation, because this is where the disocclusion times are reduced to neuromuscularly healthy levels.¹ Phase II adjustments are accomplished only after all Class I, II,

and III (Glickman)⁶ interferences are removed from the mandibular excursions bilaterally.^{1,2} Disocclusion time is stable³ once reduced, so it is not necessary to verify it at each appointment. However, it is essential to check all excursions for interfering contacts at each treatment visit, because it is possible to have an "early" posterior interference present in an excursive movement.

Phase II comprises all of the treatment visits after phase I. These adjustments are accomplished with the patient's assistance and computer analysis by the T-Scan. It is important to ask the patient a series of questions at each treatment visit to ascertain the comfort of their occlusion while it is changing:

1. Where is the most pressure in your bite?
2. Are there any "rocking points" present?
3. Do you land "squarely" or do you hit somewhere and "slide in" to your bite?
4. Do the right and left sides feel even?
5. Do you feel light in the back of your mouth?
6. Does biting down hurt your face, ears, neck, or temples?
7. Is there anything you don't like about your bite?
8. Do you feel blocked when you slide from side to side?
9. Is there any increase in tension in your face when you bite down?

Habitual closure adjustments are usually accomplished two to eight visits after the first treatment appointment. Active treatment by habitual closure adjustments is completed when the patient reports that he or she has adapted to the occlusion, is unaware of imbalances in the closure position, and thus spends little daily time evaluating the occlusion. By the time this psychological adaptation occurs, most or all symptoms should have been previously eliminated for 1 or 2 months.

The new habitual closure position is forward of both the pretreatment position and centric relation.^{1,2} As the muscles relax over time, they stretch out and push the mandible away from the face. Any attempt to retrude the mandible, as in traditional occlusal equilibration,⁴⁻⁷ would most likely negate the beneficial effects of an anterior relaxation shift. This may be one of the reasons that occlusal equilibration has not been predictably successful in treating MPDS.

Relaxation of the musculature has been reported by the patients to begin while the patient is in the chair, at the completion of the first phase of treatment when immediate complete anterior guidance is established.

Most patients have stated that their face feels "lighter," "looser," "more relaxed," or "draining," as tension begins to leave their facial muscles.^{1,2} Once this process has begun, the muscles should heal from the hyperactive state and return to normal function in a few months.

Visit 1

Prior to the commencement of any treatment, a complete oral history of the patient's MPDS should be taken and discussed by the operator and the patient. If it is necessary, other diagnostic procedures (such as magnetic resonance imaging, tomography, or transcranial radiographs) may be ordered by the operator to aid in making a proper diagnosis of myofascial pain-dysfunction syndrome. Notes are made on a form is used to list all current symptoms and their frequency and intensity, past therapies the patient has attempted, medications used and those presently in use, and how all this has affected the quality of the patient's daily life.

It is important that both on this form, and orally as well, that the patient be made aware of all risks attendant to any occlusal adjustment procedure and that the patient's informed consent be obtained. Some of the risks include (1) thinned enamel or dentinal exposure leading to tooth sensitivity; (2) changes in the vertical dimension of occlusion; and (3) damage to or perforation of crowns, fixed partial dentures, or onlays, which may require replacement after occlusal changes are complete.

The mechanical action of adjusting tooth surfaces should be accomplished with a sanding or planing motion, as opposed to a gouging motion. Enamel recontouring can be successfully achieved with a No. 6 or No. 8 round diamond in the high-speed handpiece. If the operator has a preference for other instrumentation that can achieve the desired occlusal corrections, it is satisfactory to employ them. Articulating marks should be made with Accufilm (Parkell), an extremely thin paper that has been shown to imprint few false positive marks.

When the teeth are adjusted during phase I (when most of the enamel is altered) the least amount of enamel reshaping required to effect the proper occlusal changes is the correct amount. Major enamel changes should not be made with a single adjustment. The utilization of a series of repetitive preadjustment jaw movements and markings should allow the operator to correctly and minimally alter the occlusal surfaces when establishing immediate complete an-

terior guidance. However, it is very important that the adjustments be definitive corrections to the incorrectly contacting tooth surfaces.

By distributing the adjustments of phase I over a series of corrections, and by adjusting both the mandibular and maxillary teeth, minimal adjustment to the occlusal surfaces should create the proper occlusal changes to bring about positive muscular changes.

Phase II adjustments affect considerably less enamel than phase I, and can be accomplished in either arch that the operator chooses to adjust.

Measurement of pretreatment disocclusion time. Prior to any adjustments, the Force Movie¹⁰ mode of the T-Scan is utilized to measure and calculate the pretreatment disocclusion time as previously described by Kerstein and Wright.¹ It is helpful to make a few measurements of each excursion (right, left, and protrusive) for comparisons of reliability of the length of pretreatment disocclusion time. This should then be recorded in the patient record for future comparison to the posttreatment disocclusion time.

The woman represented in Figs 2 through 11 has a pretreatment right disocclusion time of 0.860 seconds and a pretreatment left disocclusion time of 2.400 seconds (Fig 1, left excursion only). She has completed orthodontic treatment that resulted in a Class I occlusion and has been experiencing jaw tension, fatigue, clenching, bruxism, difficulty in chewing and eating, and temporal headaches for approximately 2 years.

Initiation of phase I. Treatment is commenced by air drying the teeth (both arches) in opposing posterior quadrants and marking the teeth with Accufilm, while the patient is instructed to close in maximal intercuspal position (MIP) and then commence excursive movements by sliding the mandible all the way to the right, then return to MIP, and then make a full excursion to the left and once again return to MIP. Lengthy disocclusion time is represented clinically by lines of Accufilm ink on the involved teeth. Generally these lines originate in or very near to the central fossae or marginal ridge and travel up most of the incline to the cusp tip (Figs 2 and 3). The resultant linear occlusal markings are analyzed, the interfering inclines are removed from both arches, and then the process is repeated. These interferences are also clearly shown by the T-Scan in Force Movie mode.

In Figure 2, there are lines present on the distolingual cusp of tooth 24 and on the mesiolingual cusps of teeth 26 and 27, indicating the presence of Class III interferences. Class II interferences are present on the palatal aspect of teeth 26 and 27 and a Class I interfer-




Fig 1 Patient 1. Preoperative left working disocclusion time.

ence is present on the mesio-occlusal incline of tooth 24. Anterior guidance is present on the mesial aspect of tooth 23, but it is not sufficiently steep to disocclude the posterior teeth (Class I and II interferences). The Class III interferences present are due to a lack of steepness of the contralateral pretreatment anterior guidance.

Corresponding to this pattern are Class III interferences on the distobuccal occlusal inclines of teeth 36 and 37, mesiobuccal cusp of tooth 37, and Class II interferences on the distolingual occlusal inclines of teeth 36 and 37 (Fig 3).

The Class I, II, and III interferences are removed from the excursions, but all cusp tip contacts, central fossae contacts, and marginal ridge contacts are left alone. The inclines adjacent to these proper contacts are adjusted (Fig 4). Repetition of this process is accomplished unilaterally until a proper pattern of Accufilm marks is generated.

After one adjustment of all Class I, II, and III linear interferences, the patient is instructed to re-create the same excursive movements while the teeth are remarked with Accufilm. Figure 5 shows the resultant pattern after one series of adjustments. The lines are now only rounded contacts, and many small pinpoint markings are present.

An important new contact to note is on the distobuccal surface of tooth 36. This is a Class I interference

that has resulted from the creation of more lateral anterior guidance developed through the removal of the first set of interferences. This is a common occurrence of significant importance. As the guidance is moved anteriorly through successive adjustments of the excursions, new interferences become apparent, not only in the molar region but also in the premolar region. The removal of these with each repetitive correction is imperative if disocclusion time is to be successfully reduced. The total disocclusion time is the sum of all molars and nonworking premolars in contact during an excursion. The presence of new Class I, II, or III interferences will prolong disocclusion time.

Figures 6 and 7 show the patterns that resulted after the second series of adjustment. Note the lessening of the Class I interference on the facial of tooth 36 (Fig 6). It is closer to the cusp tip, but some of it is still present. This can also be seen by the two pinpoint contacts on the mesiobuccal occlusal incline of tooth 26 (Fig 7). Class II contacts still emanate from the central fossae of teeth 36 and 37 and continue up the distolingual inclines. These correspond to the palatal inclines of teeth 26 and 27, where pinpoint red contacts are visible near and below the cusp tip contacts. Teeth 36 and 37 have early Class III contacts that still remain: on the mesiobuccal occlusal incline of tooth 37 and on the fifth cusp occlusal incline of tooth 36. It is possible to see the corresponding Class III contact on tooth 26

Figs 2 to 14 Tooth contacts: (I) Class I interference; (II) Class II interference; (III) Class III interference; (MR) marginal ridge contact; (CF) central fossa contact; (CT) cusp tip; (AG) anterior guidance contact.

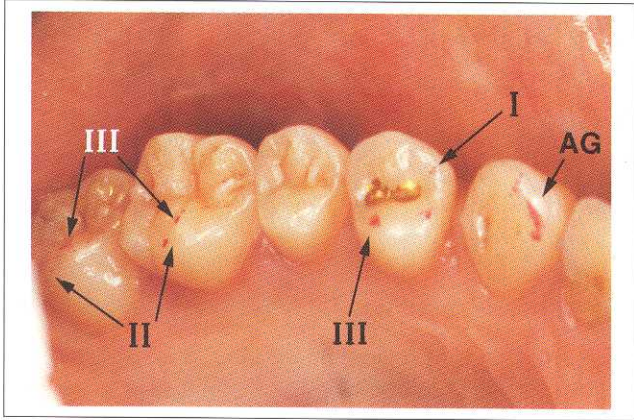


Fig 2 Patient 1. Pretreatment linear Accufilm markings, maxillary left quadrant.

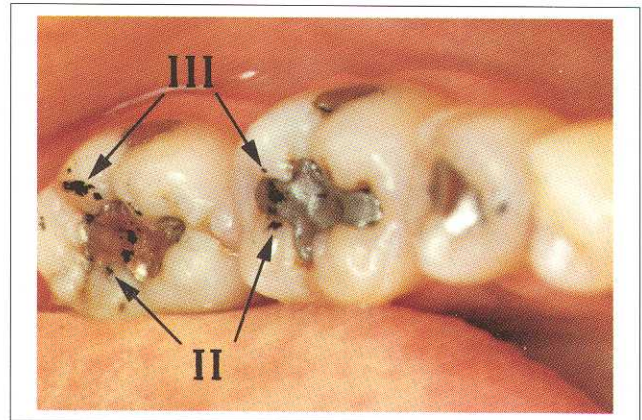


Fig 3 Patient 1. Pretreatment linear Accufilm markings, mandibular left quadrant.

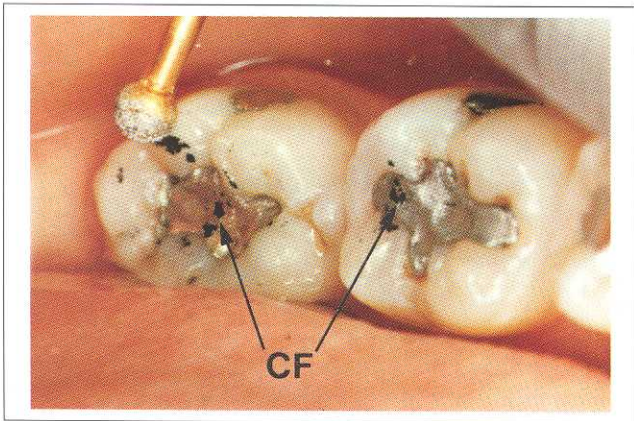


Fig 4 Patient 1. Initiation of treatment to remove Class III interference, distobuccal incline of the mandibular left second molar.

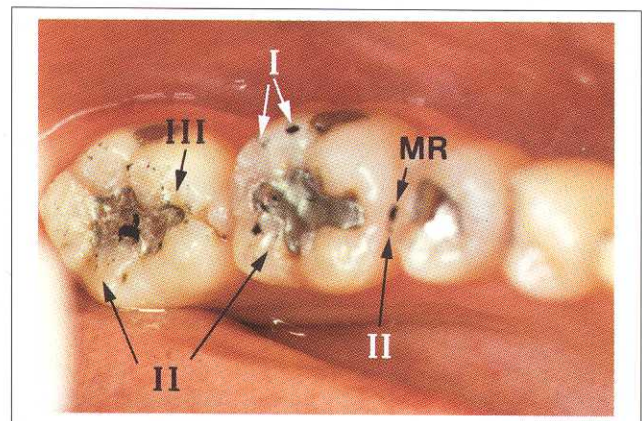


Fig 5 Patient 1. Accufilm pattern after one occlusal correction, mandibular left quadrant.

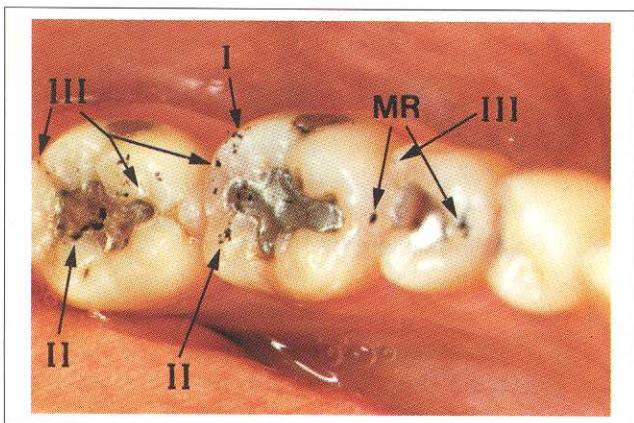


Fig 6 Patient 1. Accufilm pattern after two occlusal corrections, mandibular left quadrant.

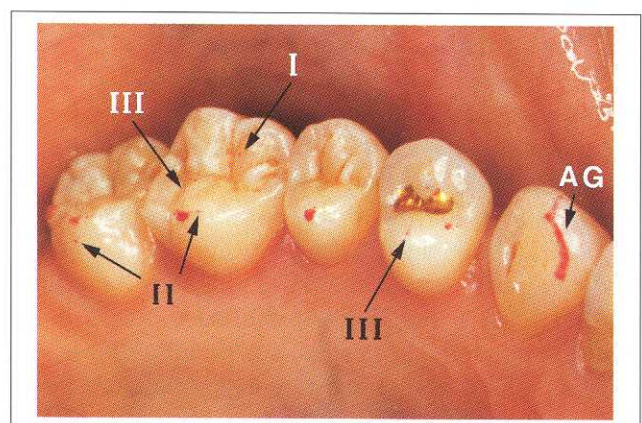


Fig 7 Patient 1. Accufilm pattern after two occlusal corrections, maxillary left quadrant.

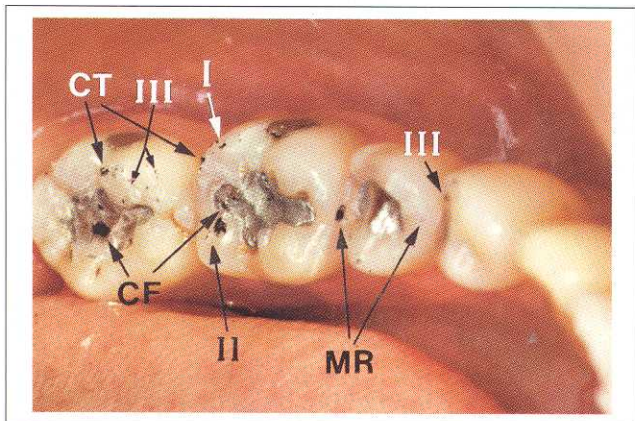


Fig 8 Patient 1. Accufilm pattern after three occlusal corrections, mandibular left quadrant.

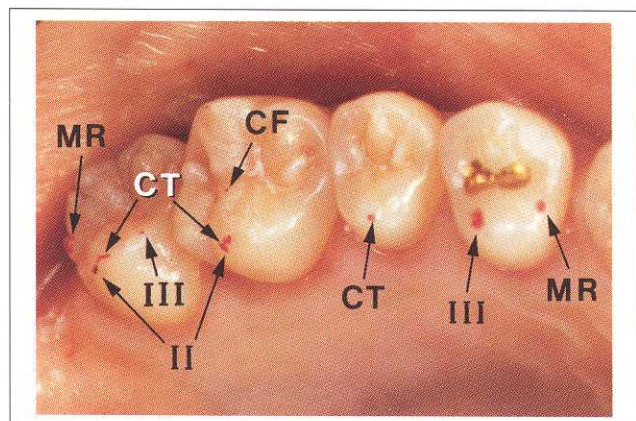


Fig 9 Patient 1. Accufilm pattern after three occlusal corrections, maxillary left quadrant.

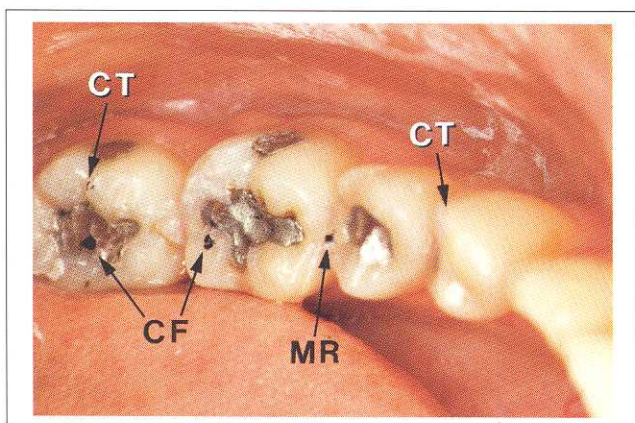


Fig 10 Patient 1. Final correct closure contacting pattern for immediate posterior disocclusion, mandibular left quadrant.

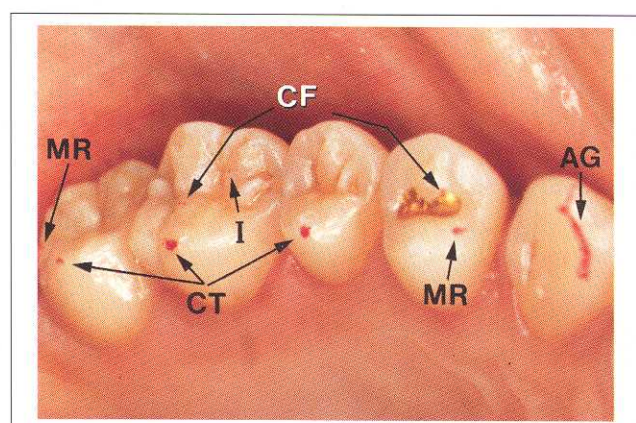


Fig 11 Patient 1. Final correct closure contacting pattern for immediate posterior disocclusion, maxillary left quadrant.

only in Fig 7. It is a pinpoint contact in the middle lingual half of the transverse ridge. New Class III interferences are present on the distoincisal aspect of tooth 35 and the palatal occlusal incline of tooth 24.

Figures 8 and 9 show the beginnings of the correct occlusal pattern, which is indicative of immediate posterior disocclusion. Solid central fossae contacts exist on both teeth 36 and 37. The buccal cusp of tooth 37 has a singular contact; tooth 36 still shows the presence of Class I and II interferences; tooth 35 has a solid distal marginal ridge contact. Tooth 34 shows the presence of a Class III interference on the distoincisal aspect of the distal marginal ridge (Fig 8); this corresponds to the large interfering contact on the distal aspect of the occlusal incline of the lingual cusp of tooth

24 (Fig 9). This is a contact that was picked up through successive occlusal corrections. Teeth 24 to 27 have very few incorrect pinpoint contacts, and palatal cusp tip, marginal ridge (teeth 24 and 27 only), and central fossae contacts are evenly distributed.

After two more occlusal corrections, the final desired pattern of contact is achieved (Figs 10 and 11). One or two contacts are present on all teeth. They are large areas of contact; all pinpoint scratches have been definitively removed. A Class I interference is still present on the mesio-occlusal incline of tooth 26. One more correction should be adequate to eliminate this interference. The remaining contacts are habitual closure contacts that are present when the patient closes together in an unguided motion. As soon as the man-

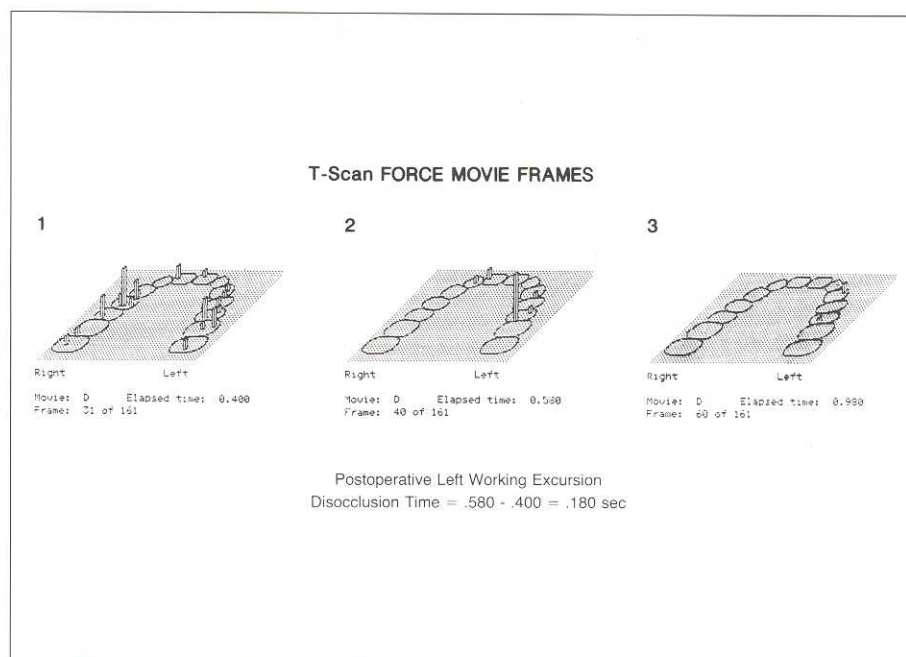


Fig 12 Patient 1. Postoperative left working disocclusion time.

dible moves laterally in either direction, posterior tooth contact no longer exists. As a result, the original inclines are no longer in contact. No lines are present in the proper contacting arrangement.

A proper pattern of occlusal markings will not show contacts on all available cusp tips, marginal ridges, and central fossae. This is the reason that properly accomplished immediate complete anterior guidance development results in a lessening of posterior tooth contact. This is the intended design of the procedure.

Also note that the guiding incline on the mesiolingual aspect of tooth 23 is uninterrupted in its course up to and over the incisal edge (Fig 11). Compared to the earlier state of tooth 23 (Fig 3), the guiding contact is far more defined. This is because tooth 23 no longer shares the guiding control with the working contacts present on teeth 24 and 34; 25 and 35; 26 and 36; and 27 and 37. The resultant guiding contacts are present only on teeth 23 and 33. This is the intended design of the procedure, to establish the immediate separation of the posterior teeth.

At this time the patient will be noticing that it is much easier to slide laterally than prior to occlusal treatment. The operator should see the guiding contacts on the canines and incisors becoming more prominent as the initial interfering inclines are removed by the repetitive adjustment process.

After completion of the first side, the same process

is applied to the contralateral quadrant. When immediate posterior disocclusion is established, the operator should reevaluate the initial side and remove any remaining interfering contacts that become evident once the second side disoccludes immediately. Balancing (Class III) interferences may recur at this time, because contralateral posttreatment anterior guidance is usually more lateral than is pretreatment guidance because of a lack of posterior guiding inclines, which previously controlled the excursion.

Visual inspection of the right and left excursions by the operator should also reveal quick posterior tooth separation bilaterally, with new found ease of accomplishment by the patient. Following this verification, the protrusive movement is assessed by having the patient close into MIP and then having him or her slide the mandible forward and back over the anterior teeth. All protrusive interferences are then removed from the posterior teeth. This process is repeated until no protrusive interferences remain.

Measurement of posttreatment disocclusion time. A new disocclusion time is measured for each excursion to verify that each is less than 0.5 seconds. If disocclusion time is not less than 0.5 seconds, the T-Scan Force Movie of the prolonged excursion will illustrate the problem areas remaining so that the operator can adjust the occlusion until disocclusion time is the correct length (Fig 12).

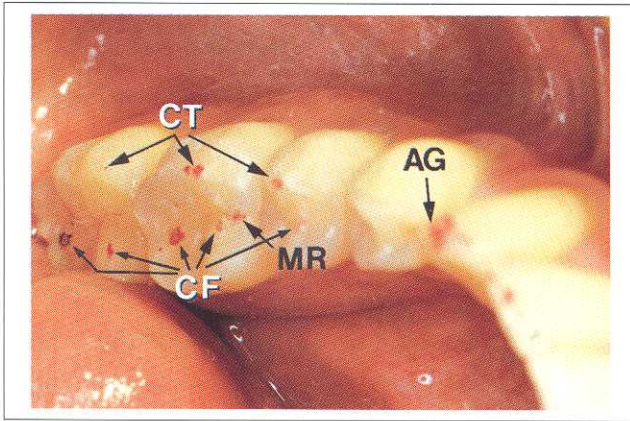


Fig 13 Patient 2. Final correct closure contacts, mandibular left quadrant.

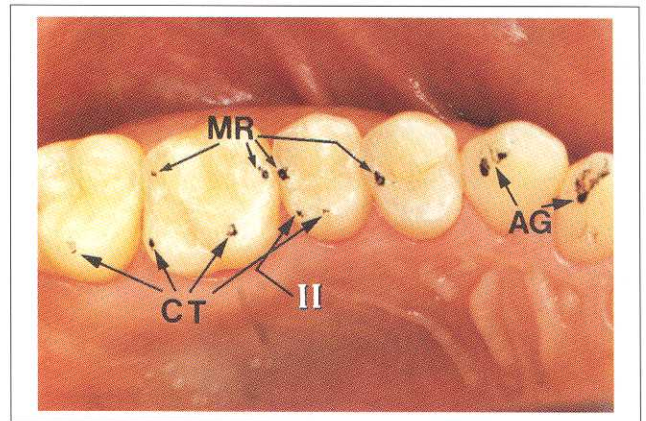


Fig 14 Patient 2. Final correct closure contacts, maxillary left quadrant.

When the excursive adjustments are completely free of inclined plane molar contact, point contact should be present on only cusp tips, and/or marginal ridges, and/or central fossae during any habitual closure (Figs 10, 11, 13, and 14). Not all stereotypical tooth contacts will be present, which results in a lessened quantity of contact in the posterior quadrants. It is this lessened quantity of posterior tooth contact that directly results in lessened disocclusion time and lessened contractile muscle activity.¹

Prior to commencing phase II, the operator should verify that the excursions are easy to achieve by the patient and that the guiding surfaces are smooth and easy to glide over. If any roughness or bumps are present, the patient will be inhibited from easy movement. These areas should be adjusted until lateral sliding is unencumbered. The guiding surfaces should have lines of tooth contact denoting the excursive control by the anterior teeth (Fig 11). This is a critical component of the procedure as initially all lines were seen posteriorly, not anteriorly. Successful disocclusion time reductions are accomplished when there are no lines of Accufilm present posteriorly, all pinpoint contacts have been removed, and Accufilm lines are visible only in the anterior region.

Initiation of phase II. Phase II adjustments, the habitual closure refinements, are commenced after all guiding surfaces are established with immediate posterior disocclusion during any mandibular excursion.

The patient is asked to close and to tap his or her teeth together repeatedly (without gliding laterally) so as to identify “high points” or areas of perceived excess tooth contact. The operator then marks the areas

with Accufilm as the patient closes into MIP only (not sliding laterally) and then adjusts the contact or contacts that are in the indicated area. It is helpful to have the patient touch the area of the involved teeth with his or her index finger as a guide for the operator.

The goal of these adjustments is to reduce, but not totally eliminate, these contacts. The reason for this is that, after developing anterior guidance, the contacts present are generally in the correct locations on each tooth. All the operator is trying to achieve is a lessening of the sense of “highness” of the involved tooth. This is accomplished by lightly sanding the pressurized contacting area.

This process is repeated for as many adjustments as are required by the patient to feel a sense of balance in the new occlusion. Once again, it is important to point out that all pinpoint Accufilm marks should be completely removed so that only solid round areas of contact remain. Figures 13 and 14 show final, correct contacting patterns of another patient. The areas of contact are solid and round; the guiding surfaces have lines on them. Only one remaining Class II interference is present on tooth 25. This contact should be removed before the patient is dismissed.

A small refinement in one part of the mouth will influence all other contacting teeth. Often the perceived high point will move from tooth to tooth or side to side while occlusal balance and comfort is being achieved. During visit 1, most of these perceived high points will be present either in the premolar region or the anterior region. This is because the molar region has a far smaller quantity of tooth contact than either of these areas once disocclusion time has been reduced.




Fig 15 T-Scan Time Mode. Premature closure contact is present.




Fig 16 T-Scan Time Mode. No premature contacts are present.

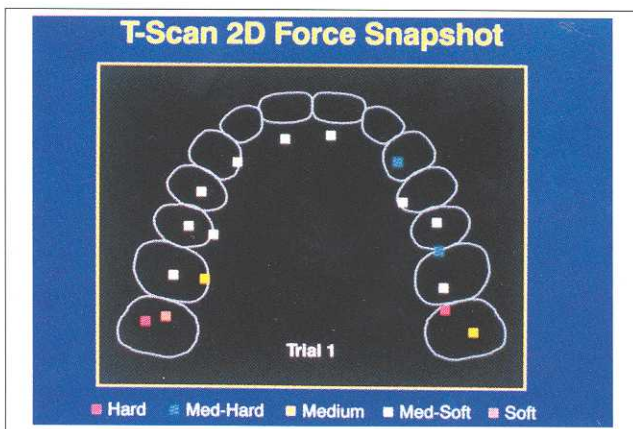


Fig 17 T-Scan Force Snapshot Mode. Pressurized contacts are present.




Fig 18 T-Scan Force Snapshot Mode. No pressurized contacts are present after occlusal corrections.

Once the patient feels a sense of balance to the new occlusion, he or she is asked the questions about occlusal comfort that were cited earlier. If the responses to these questions indicate the need for further adjustment by the operator, the teeth are marked again and refined. The patient should be unaware of pressure points or early strikes in their occlusion at the completion of visit 1.

Use of the T-Scan. Habitual closure refinements are made with the T-Scan after the patient perceives that balance has been achieved. The T-Scan will then allow the operator to precisely refine the closure position by utilizing first the Time Mode and then the Force Snapshot Mode.¹⁰

The Time Mode software is designed to distinguish the order of contacts beginning with the first closure contact at 0.00 seconds. All subsequent contacts are measured from 0.00 seconds. All closure contacts are displayed and the first three contacts are denoted by special color designation (Fig 15).

A premature contact in closure would be measured at some time distance from 0.00 seconds, ie, 0.13 seconds: first contact at 0.00, second contact at 0.13, and third contact at 0.15 seconds. In this group of contacts, the first contact precedes the second by 0.13 seconds. This contact should be adjusted until there is a smaller time frame between the first and second contacts. Following adjustment of the early contact, the new se-

quence is first contact at 0.00, second contact at 0.02, and third contact at 0.03 seconds. In this series of contacts, the first is much closer to the second, assuring the operator that no early strikes are present in the habitual closure position (Fig 16).

The Time Mode is repeatedly checked after each correction of any premature strike until a series of three to four time scans reveals no premature contacts.

Instantaneous points of excess pressure in the habitual closure position can be isolated for correction by the Force Snapshot Mode software. The most forceful contact can be viewed in either a two- or three-dimensional configuration, to allow the operator to clearly determine which contact or contacts are too forceful relative to the other contacts present when habitual closure is accomplished.

In the two-dimensional view, a five-block color chart establishes the relative forces of each contact (Fig 17). A forceful contact will be in red, and slightly less forceful but still too heavy contacts are in blue. These designations are located on the teeth throughout the scan to allow easy visualization and correction by the operator. After decreased force levels are achieved where necessary throughout the scan, there should be similar force designations of only light-to-moderate force on all contacting teeth (Fig 18).

A series of three to four similar Force Snapshots will allow the operator to verify the balance of closure forces during the habitual closure refinement phase of treatment.

Polishing. At the end of each treatment visit, all ground surfaces of the teeth should be polished with a series of instrumentation to smooth the enamel. It is important to mark the teeth with Accufilm prior to polishing, so that all proper habitual closure contacts are not removed by the polishing process. Successful polishing can be accomplished by utilizing, in series, a composite resin finishing bur (pear-shaped) in the high-speed handpiece, a white stone or point in the high-speed handpiece, and a rubber wheel (Dedeco flexi or Burelew) in the slow-speed handpiece. Other preferential instrumentation can be employed to polish the ground enamel as the individual operator requires.

Completion of visit 1. When the patient has reported a balanced, unpressurized, habitual closure position, he or she is allowed to rest for 5 to 10 minutes to make certain that the occlusion is truly comfortable. Do not send the patient home in a state of discomfort when habitual closure adjustments are made. Always question and readjust until comfort is achieved. After this rest period, if the patient still reports occlusal comfort,

it is acceptable to release him or her from treatment. He or she should be aware of a physical relaxation occurring in the masseter region at the end of visit 1.

Postoperative instructions for visit 1

The following instructions are given to the patient at the end of visit 1:

1. Do not wear any splint—it is no longer necessary, even at bedtime.
2. Take pain medication only if necessary.
3. Eat normally, but do not strain your jaw this week.
4. Keep an eye on your symptoms and the changes that are occurring so you can report them at the next appointment. Some symptoms should still be evident, but lessening, during the first few weeks—this is normal.
5. Expect your occlusion to change as your jaw musculature begins to loosen. Note the location of any areas of pressure in your occlusion and report these specific locations at your next appointment.
6. Return in 7 days for visit 2.

Anterior relaxation shift

Between visits 1 and 2, the relaxation that commences when disocclusion time is reduced has been reported to allow the masseter and temporalis to elongate and stretch out.^{1,2} Their excessive contractions have been interrupted by reducing disocclusion time; therefore, lactic acid can be metabolized and oxygen can once again enter the muscle fibers. This process results in a less contracted group of muscle fibers, hence a “longer muscle.”

The “longer” fibers move the mandible away from the face, pushing it forward. This will result in an occlusal change, perceived by the patient as “too much anterior tooth contact,” “not enough room” anteriorly, or “pressure” in the front of the mouth or side of the mouth. This is a normal consequence of muscular relaxation and will require correction at visit 2. This shift has been reported to generally occur between 3 and 5 days after visit 1.^{1,2}

Visit 2

The second treatment appointment is similar to the last half of the first appointment where habitual closure adjustments are accomplished. In the week between visits 1 and 2, muscular relaxation should have begun and the patient's occlusion should have begun to change from the way it was 1 week earlier.

Before the occlusal changes are refined, it is important to go over the list of pretreatment symptoms with the patient and have him or her reflect on the

symptom changes he or she has undergone. Note the replies and give positive reinforcement as to symptoms that have begun to subside. The patient should report a definitive reduction or change in many, if not all, pretreatment symptoms, although after 1 week some symptoms will in all probability still remain. Begin refining the closure position by asking him or her the same questions used at the end of visit 1. Adjust the occlusion until it feels comfortable and more balanced to the patient, and then let him or her rest with it for 5 to 10 minutes. Return to the operatory, question again, readjust as needed, allow rest again and, if necessary, repeat the process. Generally only a few cycles per office visit are all that are needed to improve the occlusion to a point of comfort for the patient. When the patient feels comfortable with the changes made in his or her occlusion, the T-Scan is once again employed in a similar fashion as at visit 1 to identify prematurities and pressure points that the patient cannot always detect.

Visit 2 is completed when the patient's habitual closure feels "even" and "balanced." Before the patient leaves, check the excursions for any interfering contact that may have been missed at visit 1 and adjust accordingly. When all adjustments are completed, the ground enamel should be repolished.

Visit 3 through the end of treatment

Visit 3 is 1 week after visit 2 and 14 days from visit 1. Repeat the same procedure as visit 2. After visit 3, the fourth appointment is scheduled for 2 to 3 weeks later. Each appointment that follows should be 3 to 4 weeks later. Four to six appointments may not be needed to balance the habitual position, because most muscular positional changes are ongoing for the first few weeks. The forward relaxation shift is usually complete 30 to 40 days after the first treatment visit; therefore, the mandibular position becomes stable. When the relaxation shift is complete, the patient has usually adapted to his or her new occlusion and should require very little further treatment. For most patients, visits 7 or 8, if needed, are minor correctional refinements to their occlusion. At some of these later visits it may not be necessary to adjust anything at all, as the operator will be confirming that the patient is living comfortably with his or her occlusion.

When a patient has required more than seven visits, it is often helpful to repeat visit 1 and make sure that disocclusion time is low. All interfering contact in excursions should be removed before working on the habitual closure position.

Active treatment ends when both the patient and the operator feel that muscle relaxation has reached the maximal point; no, or minimal, symptoms remain, and the patient has adapted to his or her new occlusion. The patient will not want to change the occlusion any more. This generally occurs between the fourth and eighth appointments.

Proper interpretation of patient answers to questions about symptoms and the corresponding Accufilm marks will allow the operator to alleviate muscle tension caused by subtle closure imbalances. A good mirror of in-office improvement is a report from the patient that, at the end of each visit, he or she feels more relaxed in the masseter region than when he or she came in, or that the headache is ameliorated or gone.

An empirical rule to follow is that after six to ten visits, if a symptom or group of symptoms has not been successfully alleviated, it will probably not disappear with further treatment. This is when active treatment is terminated and adjunctive symptomatic therapy may be employed. This is best defined by the experience of the operator with the different therapies available.

The contacts that create excessive muscle activity are virtually the same in every patient (see Figs 2 and 3). The interference pattern is nearly identical and can be easily interpreted by the operator once it is recognized. Lengthy disocclusion time is represented by this recurrent pattern of Glickman Class I, II, and III interferences. It may appear on only one set of contacting posterior teeth, on some contacting posterior teeth unilaterally or bilaterally, or on all contacting posterior teeth unilaterally or bilaterally.

Follow-up care

Most patients will probably need, in the first year, a few occlusal adjustments after active treatment is terminated. These visits are handled like all other phase II visits. No long-term maintenance is required once occlusal adaptation has occurred.^{2,3} Immediate complete anterior guidance development, properly performed, results in a permanent change to the teeth and the involved muscles. Once relaxation sets in, the muscles should function in a relaxed state with marked reduction in symptoms. Patients are instructed to return if they feel the need for further adjustments after active treatment has ended.

Special considerations for patients with Class II or III occlusion or open bite

Lengthy disocclusion time can be present in any skeletal relationship. Previous studies^{1,3} indicate that the reduction of disocclusion time is the significant factor in relieving contractile muscle activity, which in turn reduces chronic masseter and temporalis pain, fatigue, spasm, and muscular dysfunction. It would follow that, regardless of Angle's classification, similar improvements in the chronic dysfunction of patients with MPDS should be achieved through the development of immediate disocclusion.

This hypothesis is supported by a population study by Kerstein,¹¹ which showed that patients with Class II or open bite have the longest mean disocclusion times of all groups measured. There is also a statistically significant difference in disocclusion time between the Class I and Class III subjects; as a group, subjects with Class III occlusion have longer disocclusion time than do those with Class I occlusion.

Patients with MPDS who have Class II occlusion or anterior open bite have absolutely no ability to disocclude their posterior teeth, because their anterior teeth do not contact. These patients then have either only molar guidance of excessive duration, or shared molar and premolar guidance with a lengthy period of "early molar guidance," which precedes premolar control over the excursions.

Immediate posterior disocclusion can be accomplished in the Class II occlusal scheme by substituting the most anterior premolar in place of the anterior teeth as the guiding surfaces on the working side. The inclines of the premolars are usually steep enough to allow for immediate posterior tooth separation, once all lateral interfering contacts are removed from the molars and nonworking premolars. Composite resin guiding surfaces can often be tested and then, at the end of treatment, finished with porcelain onlays to increase the guiding inclines of the premolar region if needed.

In the protrusive movement, it is very difficult to establish immediate posterior disocclusion for the Class II patient. The final disocclusion time is generally shared between a short period of early molar guidance leading to anterior tooth contact as the mandible moves forward.

The Class III patient has little or no horizontal and vertical overlap to quickly disocclude posterior teeth. The inclines of the molars are generally steeper than the exit angles of the excursive movements in a Class

III patient; thus the posterior teeth are often the guiding factor of the occlusion. A lack of horizontal or vertical overlap results in very shallow guiding exit angles. For posterior teeth to disocclude, the posterior cuspal inclines have a shallower angle than the guiding incline; in Class III patients this is reversed.

To compensate for this reversed arrangement, the posterior teeth are adjusted so that they just miss each other when they pass each other in an excursion. This requires precise use of Accufilm and the T-Scan to ensure that disocclusion time is kept low while a minimal amount of posterior incline is adjusted. Generally, the posterior teeth resemble a monoplane configuration when immediate complete anterior guidance development is employed with a Class II or III skeletal occlusion.

Kerstein² evaluated and treated 53 patients who had MPDS. Nine had Class II occlusion and 12 had Class III. Clinical reduction of the signs and symptoms in all classes of occlusions was achieved through the removal of inclined plane molar contact, which is a lengthy period of "early molar guidance." Regardless of the Angle classification of the patient, the molars controlled the excursion, which created the condition of MPDS. This would indicate that skeletal malocclusion and jaw position may play less of a role in the etiology of MPDS than previously believed.

Discussion

Disocclusion time–reduction therapy by immediate complete anterior guidance development is a new occlusal adjustment technique made possible and assisted by new computer technology. This therapy has been shown to rapidly eliminate, or dramatically reduce, the clinical signs and symptoms of myofascial pain-dysfunction syndrome.^{1,2,3} Successful treatment has been accomplished in 1 to 3 months with the major muscular improvement occurring within 30 to 40 days following the first treatment visit.

The operator should find that this therapy is relatively easy to perform, requires little in-office overhead and materials, and has a high degree of patient acceptance, because patients are not required to wear acrylic resin splints or be involved in numerous symptomatic therapies such as chiropractic care, physical therapy, or biofeedback. The need for these therapies has been reported to be minimal when immediate complete anterior guidance development is properly executed.¹⁻³

A direct correlation has been shown to exist between contractile muscle activity of the masseter and

temporalis muscles and disocclusion time: lengthy disocclusion time leads to elevated levels of contractile muscle activity.¹ This in turn has been reported to be part of the mechanism that leads to spasm and fatigue of these muscles.^{1,2}



Successful reductions in disocclusion time by the process of immediate complete anterior guidance development restores these muscles to a state of health by directly reducing contractile muscle activity. Fatigue and spasm are subsequently interrupted, and normal muscle function returns in a few months time.

Acknowledgments

Special thanks to Dr William Maness and the Tekscan Corporation for technical assistance in the production of this manuscript.

References

1. Kerstein R, Wright N: An electromyographic and T-scan analysis of patients suffering from chronic myofascial pain dysfunction syndrome; pre- and posttreatment with immediate complete anterior guidance development. *J Prosthet Dent* 1991;66:677-686.
2. Kerstein R, Farrel S: Treatment of myofascial pain dysfunction syndrome with occlusal equilibration. *J Prosthet Dent* 1990;63:695-700.
3. Kerstein R: Stability of disclusion time: a 1-year follow up. *J Prosthet Dent* (in press).
4. Schuyler CJ: Fundamental principles in the correction of occlusal disharmony, natural and artificial. *J Am Dent Assoc* 1935;22:1193-1202.
5. Dawson PE: *Evaluation, Diagnosis and Treatment of Occlusal Problems*, ed 2. St Louis, CV Mosby Co, 1989, pp 434-440.
6. Glickman I: *Clinical Periodontology*, ed 5. Philadelphia, WB Saunders Co, 1979, pp 953, 957.
7. Tylman SD: *Tylman's Theory and Practice of Fixed Prosthodontics*, ed 7. St Louis, CV Mosby Co, 1978, p 436.
8. Maness WL, Benjamin M, Podoloff R, et al: Computerized occlusal analysis: a new technology. *Quintessence Int* 1986;15:287-293.
9. Maness WL: Force movie: a time and force view of occlusion. *Compend Contin Educ Dent* 1989;10:404-408.
10. Maness WL: *T-Scan Clinical Applications Manual*. Boston, Tekscan, Inc, 1988.
11. Kerstein R: A comparison of disclusion time of 30 chronic myofascial syndrome sufferers vs 30 "normal" subjects. *J Prosthet Dent* (in press). □



ARTICULATING-PAPER, OCCLUSION TEST FOIL, SILK, SPRAY, »HANEL-FOIL«

HANEL-GHM-DENTAL GMBH · D-7440 Nürtingen · TEL. 07022/46373 · TTX 702215 · TX 17-702215 · FAX 07022/43599